

Clinical Problem Solving

General Internal Medicine Noon Conference
Discussant: Terrence Shaneyfelt, M.D., M.P.H.
Presenter: Katri Palonen, M.D.
April 20, 2004

Case #1

- 39 y.o. female c/o "blood in urine"
- Symptoms started 6 months prior
- Treated for UTI
- 3 mos later had blood in urine following exercise
- Not related to menses

Case #1

- No resolution of symptoms with intermittent treatment for UTIs
- Mild dysuria
- Symptoms c/w stress incontinence

Case #1

- ROS: no F/C, no rash, no arthralgias, no abd pain, no edema, +two sinus infections over last 2 years.
- PMH: Obesity, HTN, pyelonephritis during last pregnancy, Rosacea
- Meds: Metrogel
- FH: no hematuria or renal disease
- SH: teacher, no T/E/D

Case #1

- PE:
 - AF, BP=132/90, P=70, T=99, Wt=170 lbs
 - Abd: soft, non-tender, no masses palpable
 - Back: no CVA tenderness
 - Otherwise exam unremarkable

Case #1

- Labs:
 - FBP nl, Ca nl
 - CBC: Hct 36, MCV 88
 - UA: 1.004/ pH6.5/ 2+blood/ -prot/ 2+LE/ 3-10 RBC/ 6-10 WBC/ rare bact/ -casts
 - Urine Cx: negative

Case #1

- Other tests:
 - U/S: R renal pelvis with echogenic material, ddx. gas in collecting system vs. numerous stones
 - CT abd: Large R renal staghorn calculus


Struvite Stones

- Formation requires
 - Increased ammonia production
 - Elevated urine pH
- Infection w/ urease-producing organism
 - Proteus, Klebsiella
- Magnesium ammonium phosphate (struvite) and CaCo₃-apatite

Struvite Stones

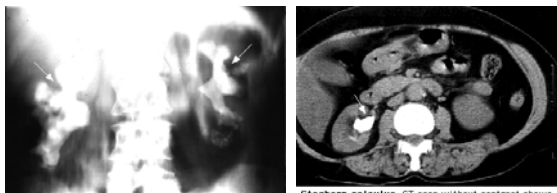
- Grow rapidly over weeks to months
- Staghorn calculus = branched calculus involving the entire renal pelvis and calyces
- Treatment of staghorn calculi:
 - Medical: often associated with stone growth and / or deterioration of renal function
 - Surgical: open surgery, percutaneous nephrolithotripsy, shock-wave lithotripsy

Struvite Stones: Urine Sediment



Phosphate crystals Urine sediment showing multiple "coffin lid" magnesium ammonium phosphate crystals which form only in an alkaline urine (pH usually above 7.0). Courtesy of Harvard Medical School.

Staghorn Calculus



Staghorn calculus Plain film of the abdomen (no contrast) showing bilateral radiopaque branched, staghorn calculi filling the collecting systems (arrows). (From Rose, BD, Pathophysiology of Renal Disease, 1st ed, McGraw-Hill, New York, 1981.)

Staghorn calculus CT scan without contrast shows large staghorn calculus in the right kidney (arrow). Courtesy of Mark D. Aronson, MD.

Case #2

- 47 y.o. female c/o nipple discharge
- Milky discharge x 1 month
- Discharge on R > L
- Denies any pain or palpable mass
- Mammogram 1 year ago, reported as normal

Case #2

- **PMH:**
 - DM, asthma, atypical chest pain, left eye blindness, s/p hysterectomy 3 months ago, depression, bi-polar disorder
- **SH:** h/o past EtOH, -tobacco / drugs
- **FH:** No breast cancer
- **Meds:**
 - Insulin, Zocor, Prilosec, Ultram, Albuterol, Atrovent, Risperdal, Lexapro, Hydroxyzine, Ativan, Gabitril (Tiagabine)
- **ROS:** -vision changes, +perimenopausal sx.

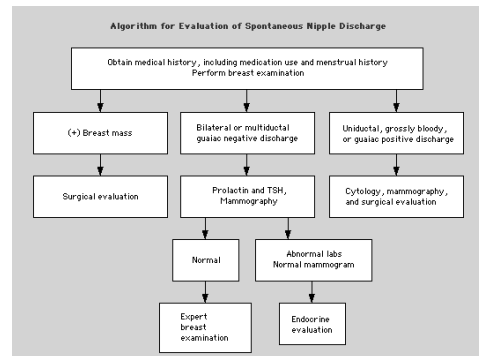
Case #2

- **PE:**
 - AF, VSS
 - **Breast exam:** no masses or skin changes, able to express milky d/c bilaterally (R>L)
 - **Axillary:** no lymphadenopathy
 - **Neuro:** no visual field defects on R
 - Rest of the exam unremarkable

Case #2

- **Labs:**
 - TSH normal
 - Prolactin 51 (<29 normal)
- **Mammogram, U/S, and ductogram all normal**

Nipple Discharge: Algorithm



Hyperprolactinemia

- **Major causes:**
 - **Physiologic:** pregnancy, lactation, stress
 - **Pituitary:** prolactinomas (micro and macro adenomas)
 - **Endocrine:** hypothyroidism, PCOS, Cushing's disease
 - **Systemic:** chronic kidney disease, cirrhosis
 - **Medications:** neuroleptics, antihypertensives (α-methyldopa, reserpine, verapamil), narcotics, cocaine

Hyperprolactinemia

- **Clinical features:**
 - Galactorrhea
 - Oligo, poly, or amenorrhea
 - Infertility
 - Decreased libido
 - Frontal headaches
 - Impaired vision (bitemporal vision loss)
 - Hypogonadism, impotence, infertility (males)

Case #3

- 75 y.o. female with hypoxia
- Routine exam with pulse ox 88%
- Denies SOB, DOE, cough, tachypnea, or chest pain / palpitations
- Non-smoker
- No weight loss

Case #3

- PMH: Depression, h/o dermatitis herpetiformis; no heart / lung dz
- SH: No Tobacco / EtOH / Illicit drugs
- FH: non-contributory
- Meds: Effexor, Trazodone, Dapsone

Case #3

- PE:
 - AF, VSS
 - Lungs: CTA bilaterally, no rales
 - CV: RRR, no S3, no JVD
 - Ext: No clubbing/edema, +cyanotic nail beds
- CXR:
 - Normal
- Labs:
 - ABG: 7.40 / 40 / 90 / 88%
 - Methemoglobin 5%

Methemoglobinemia

- Ferrous (Fe²⁺) heme oxidized to Ferric (Fe³⁺) heme
 - Ferric heme unable to bind O₂
 - Ferrous heme with increased O₂ affinity
→ Left shift in O₂ dissociation curve
- Congenital vs. acquired
 - Cytochrome b5 reductase
 - Offending agents

Methemoglobinemia

Agents Known to Cause Methemoglobinemia

Acetanilid	Naphthoquinone
p-Amino salicylic acid	<u>Naphthalene</u>
Aniline dyes	<u>Nitrites</u>
Benzene derivatives	Amyl nitrite
Clofazimine	Faryl nitrite
Chlorates	Sodium nitrite
<u>Chloroquine</u>	Nitroglycerin
<u>Dapsone</u>	Nitric oxide
Local anesthetic agents	Nitrobenzene
Benzocaine	Paraquat
Lidocaine	Phenacetin
Prilocaine	<u>Phenazopyridine</u>
Mevastone	<u>Primagine</u>
Metoclopramide	<u>Resorcinol</u>
Methylene blue*	<u>Sulfonamides</u>

*While methylene blue is a recognized treatment for methemoglobinemia, it is an agent with oxidant potential, and may worsen the clinical situation, since in individuals with glucose-6-phosphate dehydrogenase deficiency it induces acute hemolysis that can further decrease oxygen delivery to the tissues. Paradoxically, in high doses methylene blue can also increase methemoglobinemia.

Methemoglobinemia

- Diagnosis:
 - Cyanosis with normal PaO₂
 - MethHgb no longer part of standard ABG
 - Pulse oximetry with incorrect O₂ levels

Methemoglobinemia

● Treatment:

- Discontinuation of the offending agent
- Methylene Blue
 - 1-2 mg/kg IV over 5 mins
- Blood transfusion / Exchange transfusion