

Concise report

doi:10.1093/rheumatology/kes318

Safety and efficacy of intra-articular infliximab therapy for treatment-resistant temporomandibular joint arthritis in children: a retrospective study

Matthew L. Stoll¹, Anthony B. P. Morlandt², Suwat Teerawattanapong², Daniel Young³, Peter D. Waite² and Randy Q. Cron¹

Abstract

Objective. TM joint (TMJ) arthritis occurs in up to 80% of children with JIA and can result in substantial deformity. TMJ arthritis can be refractory to systemic immunosuppressive therapy and IA CS injections (IACIs). Multiple studies have shown the benefit of IA infliximab injections (IALLs) in several different joints, so we used intra-articular infliximab injections (IALLs) in JIA patients with TMJ arthritis refractory to IACIs. The objective of the study was to test the safety and efficacy of IALL therapy for TMJ arthritis.

Methods. Retrospective chart review was performed for all children with JIA treated at a single centre who received one or more IALLs. Outcomes assessed were safety of the injections as well as efficacy as evidenced by maximal incisal opening (MIO) and MRI findings.

Results. Twenty-four children underwent bilateral IALLs, all of whom had at least one follow-up visit after the final injection. All 24 tolerated the injections without any adverse events. MIOs were unchanged in patients before and after IALL. Findings of acute synovitis were present in 30/46 (65%) TMJs at baseline, 44/48 (92%) following completion of the IACI and 42/48 (88%) following completion of the IALL; findings of chronic synovitis at the three time points were 12/46 (26%), 29/48 (60%) and 38/48 (79%). Resolution of the arthritis was observed in six TMJs.

Conclusion. IALL was safe and it reversed the progression of TMJ arthritis in some patients with refractory disease. Future studies will evaluate the efficacy of infliximab vs CS injections as initial therapy for TMJ arthritis.

Key words: juvenile idiopathic arthritis, temporomandibular joint, intra-articular, infliximab.

Introduction

TM joint (TMJ) arthritis occurs in up to 80% of children with JIA [1–2]. Untreated, TMJ arthritis leads to micrognathia, poor mouth opening, facial dysmorphism and lifetime disability [3–4]. TMJ arthritis does not appear to respond fully to aggressive systemic therapy for arthritis, including anti-TNF agents [5–6]. Nevertheless, like other joints, TMJ arthritis responds to IA long-acting CSs, such

as triamcinalone hexacetonide (TH) [5, 7–10]. However, post-IA TH TMJ injections are effective in increasing inter-incisor openings and demonstrating improvement in inflammation by MRI in only ~50% of JIA patients treated in this manner. Moreover, repeated IA TH TMJ injections yield only minimal benefits in patients who have a poor response to the initial injection [7]. Multiple prior studies have evaluated the use of IA injections of TNF antagonists [11–27]. There is substantial heterogeneity among the studies with respect to the underlying condition, study design, selection of TNF inhibitor, target joints, dose and frequency of injections. However, most of the studies demonstrated short-term and, in some cases, long-lasting improvement with local TNF antagonist therapy, even among patients who have failed prior IA CS injections (IACIs) [12, 16, 19, 23, 28]. Among those, one study demonstrated that repeated IA infliximab TMJ injections

¹Department of Pediatrics, ²Department of Oral and Maxillofacial Surgery and ³Department of Radiology, University of Alabama, Birmingham, AL, USA.

Submitted 25 June 2012; revised version accepted 3 October 2012.

Correspondence to: Matthew L. Stoll, Department of Pediatrics, University of Alabama at Birmingham, 1600 7th Avenue South/Suite 210 N, Birmingham, AL 35233-1711, USA.
E-mail: mstoll@peds.uab.edu

(5 mg/injection \times 7 bilateral injections) in an adult with PsA and severe TMJ arthritis refractory to systemic infliximab and IA CSs resulted in improved TMJ symptoms and halted progression of disease as noted by CT [28]. These latter findings confirmed data from rabbit models of TMJ arthritis of improvement with IA infliximab [29, 30]. Since a significant percentage of children with JIA have continued TMJ arthritis despite aggressive systemic therapy (MTX plus biologics) in addition to IA TMJ CS injections, we began treating children with chronic progressive TMJ arthritis using IA infliximab injections (IAIIs) of the TMJs. Herein we report on the results of this therapy.

Patients and methods

Patients

This was a retrospective study conducted at a single centre (Children's of Alabama, Birmingham, AL, USA). A single oral and maxillofacial surgery group at the University of Alabama at Birmingham (UAB) performs all of the IA therapy involving the TMJ and maintains a file of such patients. Inclusion criteria were diagnosis of JIA according to the ILAR criteria [31] and completion of one or two doses of IAI therapy. Exclusion criteria were any diagnosis other than JIA. This research complied with the Declaration of Helsinki and was approved by the Institutional Review Board at UAB.

Infliximab injections

All TMJ IAIIs were performed by the same experienced oral and maxillofacial surgery group at UAB. All patients were injected under monitored anaesthesia care in an outpatient operating room. The TMJs were prepped with alcohol gauze, entered with a 23-gauge needle and lavaged with normal saline. Confirmation of entering into the superior joint space was noted by translation of the mandible upon injection, without imaging guidance; even the patients with chronic TMJ arthritis had sufficient translation to permit this manoeuvre. The joint space was then injected with 0.5–1.0 ml of 10 mg/ml infliximab (Janssen Biotech, Horsham, PA, USA), which is the maximum amount that can be inserted into this joint space. Haemostasis was achieved with gauze pads. The treatment was approved by the UAB Hospital Pharmacy and Therapeutics Committee.

Data collection

The electronic medical charts were abstracted for relevant clinical, demographic and imaging data. Maximal incisal opening (MIO) was routinely measured in the patients using the Therabite Measuring Scale (Atos Medical, West Allis, WI, USA); however, a standardized system for measurements was not employed, nor was there an adjustment for incisal vertical overbite.

Interpretation of TMJ MRI

The studies were performed as previously described [32]. Briefly, using a TMJ-specific head coil with the patient's mouth closed, we obtained 2–3 mm thick axial and

coronal T₁-weighted and fat-saturated T₂-weighted images, followed by administration of gadolinium contrast and additional T₁-weighted fat-saturated axial and coronal images. All MRIs were performed with a 1.5 Tesla scanner. Active arthritis was defined by the presence of bone marrow oedema, SF or synovial enhancement (Fig. 1), while chronic changes were defined by the presence of pannus, erosive changes, condylar flattening, or disc displacement or thinning. Although the synovial hypertrophy constituting pannus can reflect active arthritis, the presence of pannus requires a significant duration of inflammation, thus warranting defining it as a chronic change [33]. Eight different paediatric radiologists were involved in the interpretation of the actual studies.

Statistical analyses

Proportional data are reported as percentiles and continuous data as mean (s.e.m.). Comparisons of pre- vs post-operative MIOs were performed using the paired Student's *t*-test.

Results

Patient characteristics

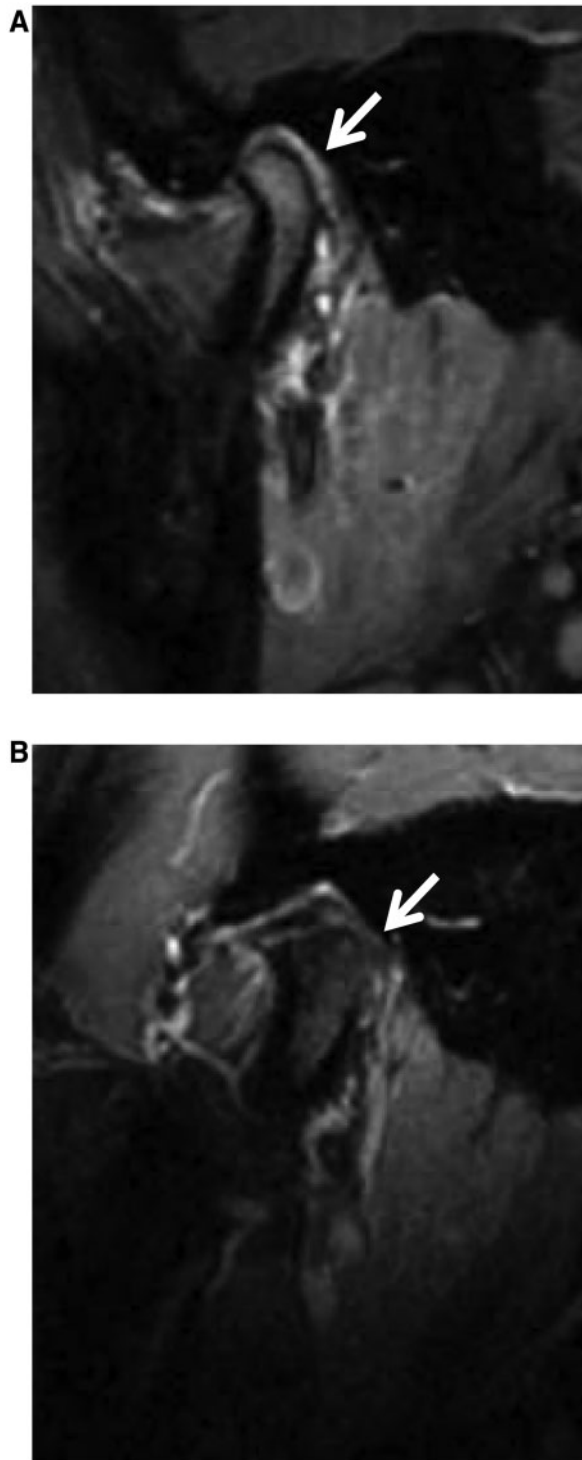
Clinical and demographic features of the 24 patients included in this study are listed in Table 1. The diagnoses were oligoarticular JIA ($n=5$), RF– polyarticular JIA ($n=9$), psoriatic JIA ($n=5$) and enthesitis-related arthritis JIA ($n=5$). None had RF+ polyarticular JIA or systemic arthritis. Fifteen (62%) of 24 patients were female. The mean (s.e.m.) age at onset of JIA was 9.1 (0.9) years (range 1.7–15.9) and the mean age of first TMJ IAI was 12.0 (0.9) years (range 2.8–18.2). Seventeen (71%) of 24 patients had received two IACIs, 6 (25%) had received three IACIs and 1 (4.2%) had only received one round before the first IAI. Twenty-two (92%) of 24 patients were on a systemic TNF inhibitor, either with (16/22) or without (6/22) concurrent therapy with conventional disease-modifying agents, 1 patient received abatacept and LEF, and 1 was receiving MTX as monotherapy. All patients had previously received IACI into both TMJs, and all received IAI bilaterally as well.

Safety

All 24 patients had at least one follow-up appointment after completion of therapy, at a mean interval of 7.8 (0.6) months after the initial IAI. They tolerated the injections without any adverse events. Specifically, there were no injection site infections, findings of s.c. atrophy, changes in skin pigmentation or reports of nerve damage or prolonged discomfort.

MIO

Paired MIO data for pre-IACI and post-IACI, along with post-IACI (pre-IAI) and post-IAI, were available for 22 patients. Before the first IACI, the mean (s.e.m.) MIO of these patients was 45.0 (1.2) mm; following the final dose of IACI, a mean of 19 (1.9) months later, the mean MIO was essentially unchanged at 44.9 (0.7) mm

Fig. 1 Imaging of TMJ arthritis.

A T₁-weighted (T₁W) fat-suppressed post-gadolinium sagittal image of the right TMJ of a 17-year-old female with psoriatic JIA (patient number 8) shows thickened and enhancing synovium (**A**; arrow). A repeat MRI (T₁W fat-suppressed post-gadolinium) in the same child 5 months later, following receipt of IA infliximab, shows considerable improvement (**B**; arrow).

($P = 0.963$). Likewise, using the post-IACI as the baseline, the mean MIO following completion of the IAI, which took place at a mean of 6.1 (0.7) months later, remained essentially unchanged at 44.6 (1.0) mm ($P = 0.888$).

Imaging

Twenty-three of 24 patients had MRIs before the initial IACI, all 24 had MRIs following the final IACI but before the initial IAI and had MRIs following the final IAI; 1 patient had a pre-IACI CT scan on account of dental braces. Changing the unit of analysis to the individual TMJ, findings of acute synovitis were present in 30/46 (65%) at baseline, 44/48 (92%) following completion of the IACI and 42/48 (88%) following completion of the IAI; findings of chronic synovitis at the three time points were 12/46 (26%), 29/48 (60%) and 38/48 (79%), respectively. All TMJs had acute synovitis on at least one MRI. Although on the whole, IAI did not appear to significantly improve the arthritis, substantial improvement was observed in several of the patients, including six TMJs (five patients) in whom resolution of the arthritis was observed post-operatively (e.g. Fig. 1).

Discussion

We performed IAIs in 24 children with JIA, all of whom had already received one to three rounds of IACI into the TMJ, in addition to aggressive systemic immunosuppressive therapy. The most important result of this study is that these injections were well tolerated, without any adverse events in all 24 patients. Although ongoing progression of TMJ disease was slowed in many patients, IAI did not appear to have a dramatic effect on arthritis resolution. However, for individual patients there was clear improvement (Fig. 1). It must be emphasized that all of these patients were on systemic immunosuppressive therapy, biologics in all but one. In addition, all had received one to three rounds of IACI, thus the patients in this study represent a highly refractory group of children and, having failed two rounds of IACI, were unlikely to respond to additional doses [7]. Since the consequences of poorly controlled inflammation in the TMJ are substantial with respect to effects on lifelong pain, function and cosmetic appearance [34], halting the progression of the arthritis is itself a worthwhile end. The optimal dosing and frequency of IAI has yet to be established. Our patients received one or two rounds of IAI, whereas a prior study reported that multiple rounds were required to observe benefit [28].

The mechanism by which infliximab injections into the TMJ may halt the progression of TMJ arthritis is unclear. In some of the prior studies using IA infliximab, improvement of manifestations of systemic inflammation were noted [13, 14, 18], questioning the requirement for IA delivery of the medicine. However, 23/24 (96%) of our patients were already receiving systemic therapy with TNF inhibition or abatacept, with some of our patients receiving infliximab doses as high as 20 mg/kg every 3–4 weeks. Indeed, we have previously reported that the TMJ may in some cases be particularly refractory to systemic

TABLE 1 Study subjects

Patient	Diagnosis	Sex	Number of prior IACIs	Interval between first IACI and first IAll, months	Age at first IAll, years	Disease duration at first IAll, months	Concurrent therapy
1	ERA	Male	3	16	12.6	20	M, T
2	oJIA	Female	2	11	11.1	18	T
3	RF– pJIA	Male	3	20	9.7	22	T
4	PsJIA	Male	3	25	15.9	43	M, T
5	RF– pJIA	Female	2	16	9.4	18	M, T
6	RF– pJIA	Female	3	32	5.6	43	T
7	ERA	Female	2	16	15.5	19	M, T
8	PsJIA	Female	2	11	17.3	27	M, T
9	PsJIA	Male	2	14	13.7	17	M, T
10	RF– pJIA	Female	2	39	9.3	47	T
11	RF– pJIA	Female	2	30	14.8	36	M, T
12	ERA	Male	2	8	10.2	47	M, T
13	PsJIA	Female	2	15	12.2	16	M
14	ERA	Male	2	33	18.2	42	M, T
15	RF– pJIA	Female	2	19	10.3	41	T
16	oJIA	Female	2	27	11.2	81	Ab, L
17	oJIA	Female	2	14	17.3	17	AZA, T
18	PsJIA	Female	2	34	5.4	37	T
19	oJIA	Female	2	21	17.1	103	M, T
20	ERA	Male	3	23	13.8	34	L, T
21	RF– pJIA	Female	3	24	14.3	26	M, T
22	oJIA	Female	1	9	2.8	14	M, T
23	RF– pJIA	Male	2	21	5.6	45	M, T
24	RF– pJIA	Male	2	9	13.9	13	M, T

Ab: abatacept; ERA: enthesitis-related arthritis; M: MTX; oJIA: oligoarticular JIA; pJIA: polyarticular JIA; PsJIA: psoriatic JIA; T: TNF inhibitor.

immunosuppressive therapy [5, 6]. Therefore the local delivery itself must mediate its therapeutic effect; prior studies have shown decreased cellular infiltrates and cytokine production following IA administration of TNF inhibitors [12, 17, 18], although no study compared histological or other changes in patients receiving systemic vs IA TNF inhibition.

This study has several limitations. Our numbers were fairly limited, we did not use a standardized protocol for measurement of MIO and variability in the measurements can be introduced by dental exfoliation and eruption; although it is possible that standardized measurements might have improved their accuracy and changed our findings, no definite conclusions can be drawn. The other major limitation of this study is that the reviews of the TMJ MRIs were not performed blinded to therapy, and no standardized protocol was used to grade them. The strength of this study is that we propose a novel therapy that adds to the range of options for refractory TMJ arthritis. Although previous investigators have reported on IA TNF inhibitors in patients with inflammatory arthritides [11–28, 35], this is the first study in children, is only the second study to report on IA infliximab into the TMJ, is one of the largest studies published on the use of IA TNF inhibitors, and included both clinical and imaging outcomes and subjects who were highly refractory to aggressive systemic and local immunosuppressive therapy.

Future studies should compare IA infliximab with IACI for initial treatment of TMJ arthritis.

Rheumatology key messages

- IAll was well tolerated in children with JIA and may have halted the progression of arthritis in some cases.
- Future studies will clarify the role of IAll in the management of TMJ arthritis.

Acknowledgements

The authors wish to acknowledge Dr Joe B. LaRussa and Cornelia B. LaRussa for their support of the research efforts of our division. We also wish to acknowledge Dr Roberto Caricchio (Temple University) for assisting with the interpretation of an Italian-language manuscript. We also thank our academic colleagues in paediatric rheumatology and in radiology at Children's of Alabama for their care and analysis of this patient cohort.

Funding: This work was supported by the Arthritis Foundation, Alabama Chapter Endowed Chair in Pediatric Rheumatology to R.Q.C.

Disclosure statement: The authors have declared no conflicts of interest.

References

- Weiss PF, Arabshahi B, Johnson A *et al*. High prevalence of temporomandibular joint arthritis at disease onset in children with juvenile idiopathic arthritis, as detected by magnetic resonance imaging but not by ultrasound. *Arthritis Rheum* 2008;58:1189–96.
- Muller L, Kellenberger CJ, Cannizzaro E *et al*. Early diagnosis of temporomandibular joint involvement in juvenile idiopathic arthritis: a pilot study comparing clinical examination and ultrasound to magnetic resonance imaging. *Rheumatology* 2009;48:680–5.
- Larheim TA, Haanaes H. Micrognathia, temporomandibular joint changes and dental occlusion in juvenile rheumatoid arthritis of adolescents and adults. *Scand J Dent Res* 1981;89:329–38.
- Karhulahti T, Ylijoki H, Ronning O. Mandibular condyle lesions related to age at onset and subtypes of juvenile rheumatoid arthritis in 15-year-old children. *Scand J Dent Res* 1993;101:332–8.
- Arabshahi B, Dewitt EM, Cahill AM *et al*. Utility of corticosteroid injection for temporomandibular arthritis in children with juvenile idiopathic arthritis. *Arthritis Rheum* 2005;52:3563–9.
- Stoll ML, Sharpe T, Beukelman T *et al*. Risk factors for temporomandibular joint arthritis in children with juvenile idiopathic arthritis. *J Rheumatol* 2012;39:1880–7.
- Ringold S, Torgerson TR, Egbert MA, Wallace CA. Intraarticular corticosteroid injections of the temporomandibular joint in juvenile idiopathic arthritis. *J Rheumatol* 2008;35:1157–64.
- Ringold S, Cron RQ. The temporomandibular joint in juvenile idiopathic arthritis: frequently used and frequently arthritic. *Pediatr Rheumatol Online J* 2009;7:11.
- Parra DA, Chan M, Krishnamurthy G *et al*. Use and accuracy of US guidance for image-guided injections of the temporomandibular joints in children with arthritis. *Pediatr Radiol* 2010;40:1498–504.
- Stoll ML, Good J, Sharpe T *et al*. Intra-articular corticosteroid injections to the temporomandibular joints are safe and appear to be effective therapy in children with juvenile idiopathic arthritis. *J Oral Maxillofac Surg* 2012;70:1802–7.
- Bokarewa M, Tarkowski A. Local infusion of infliximab for the treatment of acute joint inflammation. *Ann Rheum Dis* 2003;62:783–4.
- Ahern MJ, Campbell DG, Weedon H, Papangelis V, Smith MD. Effect of intra-articular infliximab on synovial membrane pathology in a patient with a seronegative spondyloarthropathy. *Ann Rheum Dis* 2008;67:1339–42.
- Andonopoulos AP, Meimaris N, Daoussis D, Bounas A, Yiannopoulos G. Intra-articular anti-tumor necrosis factor alpha antibody in recalcitrant arthritis of Behcet's disease. *Clin Exp Rheumatol* 2003;21(4 Suppl 30):S57–8.
- Bello S, Bonali C, Serafino L *et al*. [Intra-articular therapy with infliximab in psoriatic arthritis: efficacy and safety in refractory monoarthritis]. *Reumatismo* 2010;62:46–50.
- Bliddal H, Terslev L, Qvistgaard E *et al*. Safety of intra-articular injection of etanercept in small-joint arthritis: an uncontrolled, pilot-study with independent imaging assessment. *Joint Bone Spine* 2006;73:714–7.
- Conti F, Ceccarelli F, Priori R *et al*. Intra-articular infliximab in patients with rheumatoid arthritis and psoriatic arthritis with monoarthritis resistant to local glucocorticoids. Clinical efficacy extended to patients on systemic anti-tumor necrosis factor alpha. *Ann Rheum Dis* 2008; 67:1787–90.
- Cui Y, Xiao Z, Shuxia W *et al*. Computed tomography guided intra-articular injection of etanercept in the sacroiliac joint is an effective mode of treatment of ankylosing spondylitis. *Scand J Rheumatol* 2010;39:229–32.
- Fiocco U, Sfriso P, Oliviero F *et al*. Synovial effusion and synovial fluid biomarkers in psoriatic arthritis to assess intraarticular tumor necrosis factor-alpha blockade in the knee joint. *Arthritis Res Ther* 2010;12:R148.
- Hobbs K. Chronic sarcoid arthritis treated with intra-articular etanercept. *Arthritis Rheum* 2005;52:987–8.
- Kobak S. Osteonecrosis and monoarticular rheumatoid arthritis treated with intra-articular adalimumab. *Mod Rheumatol* 2008;18:290–2.
- Liang DF, Huang F, Zhang JL *et al*. [A randomized, single-blind, parallel, controlled clinical study on single intra-articular injection of etanercept in treatment of inflammatory knee arthritis]. *Zhonghua Nei Ke Za Zhi* 2010;49:930–4.
- Nikas SN, Temekonidis TI, Zikou AK *et al*. Treatment of resistant rheumatoid arthritis by intra-articular infliximab injections: a pilot study. *Ann Rheum Dis* 2004;63:102–3.
- O'Shea FD, Haroon N, Salonen DC, Inman RD. Clinical and radiographic response to a local infliximab injection in a patient with chronic sacroiliitis. *Nat Clin Pract Rheumatol* 2009;5:171–3.
- Sakellariou GT, Kakavouli G, Chatzigiannis I. Intraarticular injection of infliximab. *J Rheumatol* 2006;33:1912–1913.
- Schatteman L, Gyselbrecht L, De Clercq L, Mielants H. Treatment of refractory inflammatory monoarthritis in ankylosing spondylitis by intraarticular injection of infliximab. *J Rheumatol* 2006;33:82–5.
- Boesen M, Boesen L, Jensen KE *et al*. Clinical outcome and imaging changes after intraarticular (IA) application of etanercept or methylprednisolone in rheumatoid arthritis: magnetic resonance imaging and ultrasound-Doppler show no effect of IA injections in the wrist after 4 weeks. *J Rheumatol* 2008;35:584–91.
- van der Bijl AE, Teng YK, van Oosterhout M *et al*. Efficacy of intraarticular infliximab in patients with chronic or recurrent gonarthritis: a clinical randomized trial. *Arthritis Rheum* 2009;61:974–8.
- Alstergren P, Larsson PT, Kopp S. Successful treatment with multiple intra-articular injections of infliximab in a patient with psoriatic arthritis. *Scand J Rheumatol* 2008; 37:155–7.
- Ohtani T, Habu M, Khanal A *et al*. Local effects of intra-articular injection of anti-rabbit tumor necrosis factor alpha monoclonal antibody in antigen-induced arthritis of the rabbit temporomandibular joint. *J Oral Pathol Med* 2012;41:96–105.

- 30 Stoustrup P, Kristensen KD, Kuseler A *et al.* Condylar lesions in relation to mandibular growth in untreated and intra-articular corticosteroid-treated experimental temporomandibular joint arthritis. *Clin Exp Rheumatol* 2010;28:576-83.
- 31 Petty RE, Southwood TR, Manners P *et al.* International League of Associations for Rheumatology classification of juvenile idiopathic arthritis: second revision, Edmonton, 2001. *J Rheumatol* 2004;31:390-2.
- 32 Cahill AM, Baskin KM, Kaye RD *et al.* CT-guided percutaneous steroid injection for management of inflammatory arthropathy of the temporomandibular joint in children. *AJR Am J Roentgenol* 2007;188:182-6.
- 33 Scutellari PN, Orzincolo C. Rheumatoid arthritis: sequences. *Eur J Radiol* 1998;27(Suppl. 1):S31-8.
- 34 Arabshahi B, Cron RQ. Temporomandibular joint arthritis in juvenile idiopathic arthritis: the forgotten joint. *Curr Opin Rheumatol* 2006;18:490-5.
- 35 Bliddal H, Terslev L., Qvistgaard E *et al.* A randomized, controlled study of a single intra-articular injection of etanercept or glucocorticosteroids in patients with rheumatoid arthritis. *Scand J Rheumatol* 2006;35:341-5.