



Radiotherapy plus cetuximab for locoregionally advanced head and neck cancer: 5-year survival data from a phase 3 randomised trial, and relation between cetuximab-induced rash and survival

James A Bonner, Paul M Harari, Jordi Giral, Roger B Cohen, Christopher U Jones, Ranjan K Sur, David Raben, Jose Baselga, Sharon A Spencer, Junming Zhu, Hagop Youssoufian, Eric K Rowinsky, K Kian Ang

Summary

Background Previous results from our phase 3 randomised trial showed that adding cetuximab to primary radiotherapy increased overall survival in patients with locoregionally advanced squamous-cell carcinoma of the head and neck (LASCCHN) at 3 years. Here we report the 5-year survival data, and investigate the relation between cetuximab-induced rash and survival.

Methods Patients with LASCCHN of the oropharynx, hypopharynx, or larynx with measurable disease were randomly allocated in a 1:1 ratio to receive either comprehensive head and neck radiotherapy alone for 6–7 weeks or radiotherapy plus weekly doses of cetuximab: 400 mg/m² initial dose, followed by seven weekly doses at 250 mg/m². Randomisation was done with an adaptive minimisation technique to balance assignments across stratification factors of Karnofsky performance score, T stage, N stage, and radiation fractionation. The trial was un-blinded. The primary endpoint was locoregional control, with a secondary endpoint of survival. Following discussions with the US Food and Drug Administration, the dataset was locked, except for queries to the sites about overall survival, before our previous report in 2006, so that an independent review could be done. Analyses were done on an intention-to-treat basis. Following completion of treatment, patients underwent physical examination and radiographic imaging every 4 months for 2 years, and then every 6 months thereafter. The trial is registered at www.ClinicalTrials.gov, number NCT00004227.

Findings Patients were randomly assigned to receive radiotherapy with (n=211) or without (n=213) cetuximab, and all patients were followed for survival. Updated median overall survival for patients treated with cetuximab and radiotherapy was 49.0 months (95% CI 32.8–69.5) versus 29.3 months (20.6–41.4) in the radiotherapy-alone group (hazard ratio [HR] 0.73, 95% CI 0.56–0.95; p=0.018). 5-year overall survival was 45.6% in the cetuximab-plus-radiotherapy group and 36.4% in the radiotherapy-alone group. Additionally, for the patients treated with cetuximab, overall survival was significantly improved in those who experienced an acneiform rash of at least grade 2 severity compared with patients with no rash or grade 1 rash (HR 0.49, 0.34–0.72; p=0.002).

Interpretation For patients with LASCCHN, cetuximab plus radiotherapy significantly improves overall survival at 5 years compared with radiotherapy alone, confirming cetuximab plus radiotherapy as an important treatment option in this group of patients. Cetuximab-treated patients with prominent cetuximab-induced rash (grade 2 or above) have better survival than patients with no or grade 1 rash.

Funding ImClone Systems, Merck KGaA, and Bristol-Myers Squibb.

Introduction

Squamous-cell cancers of the head and neck with advanced primary lesions, with or without regional lymph-node metastases, are challenging to treat effectively while maintaining the function of vital healthy structures. Extensive surgical resection of the primary tumour and regional cervical lymphatics used to be the standard of care in the USA.^{1,2} More recently, additional organ-preserving strategies using either radiation alone^{3,4} or chemoradiotherapy⁵ have become a treatment option for these patients, and have been the focus of much investigation.

The systematic clinical investigation of organ-preserving radiotherapy and chemoradiotherapy regimens suggested

that these regimens could produce overall survival results as good as surgical resection for patients with locoregionally advanced squamous-cell cancer of the head and neck (LASCCHN),^{3–9} thus radiation had become a cornerstone of treatment for patients with LASCCHN by the 1990s.^{3,4} The addition of chemotherapy to radiotherapy has also been extensively investigated. A recent meta-analysis of 87 randomised trials that compared locoregional treatment with or without chemotherapy found that the addition of chemotherapy to locoregional treatment was associated with an absolute survival advantage of 4.5% at 5 years.¹⁰ However, chemoradiotherapy is associated with increased toxicity

Published Online
November 7, 2009
DOI:10.1016/S1470-2045(09)70311-0

University of Alabama, Birmingham, AL, USA (Prof J A Bonner MD, Prof S A Spencer MD); University of Wisconsin, Madison, WI, USA (Prof P M Harari MD); Vall D'Hebron University Hospital, Barcelona, Spain (Prof J Giral MD, Prof J Baselga MD); Fox Chase Cancer Center, Philadelphia, PA, USA (Prof R B Cohen MD); Radiological Associates of Sacramento, Sacramento, CA, USA (C U Jones MD); McMaster University, Hamilton Regional Cancer Centre, Hamilton, ON, Canada (Prof R K Sur MD); University of Colorado, Aurora, CO, USA (Prof D Raben MD); ImClone Systems Corporation, Branchburg, NJ, USA (J Zhu PhD, H Youssoufian MD, E K Rowinsky MD); and University of Texas MD Anderson Cancer Center, Houston, TX, USA (Prof K K Ang MD)

Correspondence to: Prof James A Bonner, Department of Radiation Oncology, University of Alabama at Birmingham, 1824 6th Avenue South, Birmingham, AL, USA
jabonner@uabmc.edu

compared with radiotherapy alone.^{8–12} Adding to the complexity of treatment decisions, altered fractionated radiotherapy has been shown to be associated with a survival advantage compared with once-daily radiotherapy,¹¹ but can be difficult to deliver with chemotherapy.¹² Therefore, a judicious approach to the optimal use of altered fractionated radiotherapy with or without chemoradiotherapy is warranted. Mitigating toxicity remains an important goal in developing new treatment approaches for patients with LASCCHN.^{11,12}

High levels of epidermal growth factor receptor (EGFR) expression, which have been seen in approximately 90% of squamous-cell cancers of the head and neck,¹³ have been shown to correlate with worse clinical outcome,¹⁴ decreased response to radiotherapy, and increased locoregional recurrence following definitive radiotherapy.¹⁵ Preclinical studies in human squamous-cell cancer of the head and neck cell lines have shown that the inhibition of EGFR results in radiosensitisation.^{16–18} Cetuximab is an IgG1 monoclonal antibody that exclusively targets EGFR with high affinity, and inhibits endogenous ligand binding, thereby blocking receptor dimerisation, tyrosine kinase phosphorylation, and signal transduction.^{19–23} Cetuximab has been shown to inhibit growth across various squamous-cell carcinoma cell lines, and exposure to cetuximab before or after radiation increases the radiosensitivity of such cells.^{13,17,18} Furthermore, in-vitro and in-vivo studies have shown that there is synergy between cetuximab and radiotherapy, with the combination resulting in a greater reduction in cellular proliferation than either treatment alone.^{13,17,18}

In 1998, based on preclinical and phase 1b and 2a clinical studies, we designed a randomised trial to test

the value of adding cetuximab to radiotherapy in the definitive treatment of patients with LASCCHN.^{13,16–18,24} Recruitment was completed in March, 2002, and, compared with radiotherapy alone, the addition of cetuximab was shown to be associated with a 13% absolute improvement in locoregional control at 3 years (34% vs 47%) and a 10% absolute improvement in survival at 3 years (45% vs 55%).²⁵ The previously published results of all trial endpoints were reported after locking the dataset to further input. After the dataset was locked, a thorough independent review was undertaken. This decision was made based on discussions with the US Food and Drug Administration (FDA). The treating sites were asked to provide only information regarding overall survival following the initiation of the independent review. Here we report an update of survival, and aim to use this updated data for subgroup analyses of patient and tumour characteristics.

Data from several studies across multiple cancers (including recurrent/metastatic squamous-cell cancer of the head and neck, colorectal, non-small cell lung cancer, and pancreatic cancer) suggest a correlation between overall survival and the presence and/or intensity of cetuximab-induced acne-like rash.^{26–29} Thus, we also assess the significance of cetuximab-induced rash in the context of these updated survival data.

Methods

Patients

As previously described in detail,²⁵ following the approval of the protocol by the institutional review board of each participating institution, patients with stage III or IV non-metastatic, measurable cancers of the oropharynx, hypopharynx, or larynx were randomly assigned to either radiotherapy alone or radiotherapy with cetuximab. Only those patients judged to be medically suitable for definitive radiotherapy, and who had a Karnofsky performance score (KPS) of at least 60 with normal haematopoietic, hepatic, and renal function were eligible for inclusion. Investigators were not instructed to select patients on the basis of characteristics other than the stated eligibility criteria.

Procedures

Radiotherapy consisted of one of the following three regimens:²⁵ once-daily radiotherapy delivered at 2 Gy per day to a total dose of 70 Gy to gross disease; twice-daily radiotherapy delivered as 1·2 Gy in two separate fractions each day (separated by ≥ 6 h) to a total dose of 72·0–76·8 Gy; and concomitant boost radiotherapy delivered as 1·8 Gy per day for 30 fractions, with a second fraction of 1·5 Gy delivered more than 6 h after the first fraction during the last 12 days of treatment for a total dose of 72 Gy.

The radiation regimens were required to deliver at least 50–54 Gy to uninvolved nodal areas of the neck, and grossly involved neck nodes could receive the reduced gross disease dose of 60 Gy (reduced from the gross

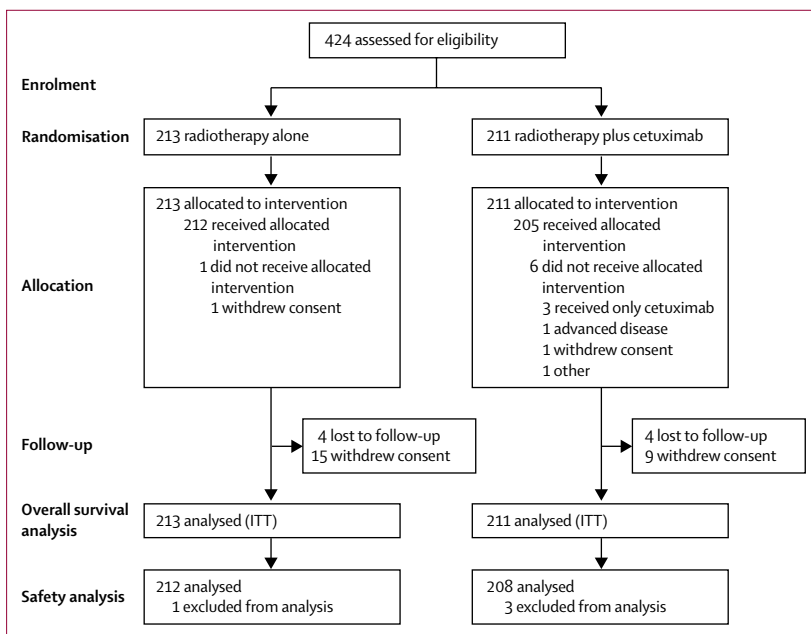


Figure 1: Trial profile

disease dose) if the investigators planned a neck dissection after radiotherapy. For patients who received concomitant cetuximab with radiotherapy, an initial loading dose of 400 mg/m² was delivered over 120 min, 1 week before the start of radiotherapy. These patients then received seven weekly infusions of 250 mg/m² of cetuximab during radiotherapy. The details of the infusions and the radiotherapy quality assurance have been outlined previously.²⁵

Patients were assessed at regular intervals after the completion of radiotherapy. Follow-up assessments began 4 weeks after the completion of radiotherapy and included history taking, physical examination, and CT imaging of the head and neck. Following an 8-week assessment, follow-up examinations were done every 4 months for 2 years, and every 6 months thereafter. More frequent visits were at the discretion of the individual investigator. The treatment sites were asked to provide only survival information after the dataset had been locked: before this time, patients were assessed for recurrence and toxicities by the Radiation Therapy Oncology Group (RTOG) criteria.³⁰ The prognostic significance of human papillomavirus (HPV) status has only become clear over the past 5 years, and therefore no HPV testing was done in this trial.

Randomisation and masking

The trial was not blinded because cetuximab was known to cause an acneiform rash. After discussions with the FDA, it was felt that physician and patient blinding was not possible. An interactive voice response system (IVRS) enabled individual sites to obtain a randomisation number and treatment group for a given patient. This process was done by PharmaNet medical monitors (Princeton, NJ, USA). Authorised individuals at each institution called the IVRS system (using a pass code) and responded to certain prompts. The system then faxed the institution with details of the assigned treatment group. Randomisation was done using a minimisation technique, which used an adaptive balancing algorithm.³¹ Patients were stratified according to their KPS (60–80 vs 90–100), nodal involvement (N0 vs N+), tumour stage (T1–3 vs T4), and radiotherapy fractionation.

Statistical analysis

The sample size was determined using a two-sided log-rank test and the hypothesis that the addition of cetuximab to radiotherapy would increase locoregional control at 1 year from 44% to 57% based on historical studies and phase 2 assessments with cetuximab and radiotherapy in this setting. 208 patients per group were required to detect this difference with a 90% power and 5% significance level. This analysis was based on an expected accrual period of 18 months and an additional follow-up period of 12 months (two-sided log-rank test). This sample size would provide an 80% power to detect a

	Radiotherapy (N=213)	Radiotherapy plus cetuximab (N=211)
Age (years; median [range])	58 (35–83)	56 (34–81)
Sex (male/female)	169 (79)/44 (21)	171 (81)/40 (19)
KPS (90–100/60–80/unknown)	141/71/1 (66/33/1)	147/63/1 (69/30/1)
N stage (N0/N+)	41/172 (19/81)	43/168 (20/80)
T stage (T1–3/T4)	153/60 (72/28)	152/59 (72/28)
Radiotherapy fractionation		
Concomitant boost	119 (56)	118 (56)
Once a day	57 (27)	54 (26)
Twice a day	37 (17)	39 (18)
Primary tumour site		
Oropharynx	135 (63)	118 (56)
Hypopharynx	27 (13)	36 (17)
Larynx	51 (24)	57 (27)
AJCC (stage III/IV)	51/161 (24/76)	55/156 (26/74)
EGFR status		
Detectable	170 (80)	166 (79)
Non-detectable	3 (1)	0
Unknown	40 (19)	45 (21)
Neck dissection	53 (25)	51 (25)
Salvage surgery	25 (12)	29 (14)
Secondary radiation	12 (6)	13 (6)
Secondary chemotherapy	44 (21)	37 (18)

Data are n (%). KPS=Karnofsky performance score. AJCC=American Joint Committee on Cancer. EGFR=epidermal growth factor receptor.

Table 1: Patient and tumour characteristics

50% increase in median survival. Details of the analysis have been previously published.²⁵ Additional follow-up regarding locoregional control was not captured after our previous reports; therefore, this endpoint is not updated. Survival was assessed as a standard stratified log-rank comparison of the two treatment groups on an intention-to-treat basis,³² and a forest plot made as previously described.³³

The primary endpoint was the duration of locoregional control, which was defined as the time without progression of locoregional disease or death. Secondary endpoints of survival, and quality of life were assessed. The best response during the first year was used in the assessment of response and has been previously reported.²⁵ Quality of life has also been previously reported.³⁴ Information regarding late toxicities was not collected.

Patients who received cetuximab were assessed for an acneiform rash, which was defined by the Coding Symbols for a Thesaurus of Adverse Reaction Terms (COSTART) as acne; rash; maculopapular rash; and exfoliative dermatitis. In a previous publication,²⁵ pustular rash and dry skin were included, but further review with the investigators suggested that these terms were not being used for acneiform rash. Patients who had either no rash or grade 1 rash were classed as having mild rash. Patients who developed a grade 2–4 rash were classed as having prominent rash. A backward stepwise Cox regression analysis was done to control for potential

	Radiotherapy (N=212)			Radiotherapy plus cetuximab (N=208)		
	All grades	Grade 3/4	Grade 4	All grades	Grade 3/4	Grade 4
Skin reaction*	200 (94.3%)	45 (21.2%)	3 (1.4%)	204 (98.1%)	73 (35.1%)	4 (1.9%)
Mucositis/stomatitis†	199 (93.9%)	110 (51.9%)	9 (4.2%)	194 (93.3%)	116 (55.8%)	13 (6.3%)
Dysphagia	134 (63.2%)	63 (29.7%)	3 (1.4%)	136 (65.4%)	54 (26.0%)	1 (0.5%)
Xerostomia‡	150 (70.8%)	6 (2.8%)	0 (0%)	150 (72.1%)	10 (4.8%)	0 (0%)
Acneiform rash§	21 (9.9%)	3 (1.4%)	0 (0%)	174 (83.7%)	35 (16.8%)	1 (0.5%)
Infusion reaction¶	4 (1.9%)	0 (0%)	0 (0%)	32 (15.4%)	6 (2.9%)	2 (1.0%)

*Skin reaction includes all Coding Symbols for a Thesaurus of Adverse Reaction Terms (COSTART) terms in the Skin and Appendages body system. †Mucositis/stomatitis includes COSTART terms aphthous stomatitis; gingivitis; glossitis; mouth ulceration; mucous membrane disorder; stomatitis; and ulcerative stomatitis. ‡Xerostomia is COSTART term dry mouth. §Acneiform rash includes COSTART terms acne; rash; maculopapular rash; exfoliative dermatitis. ¶Infusion reaction includes COSTART terms allergic reaction; anaphylactoid reaction; and/or fever; chills; or dyspnoea on the first day of treatment. ||Statistically significant (p<0.05) difference between the treatment groups; Fisher's exact test.

Table 2: Most common adverse events

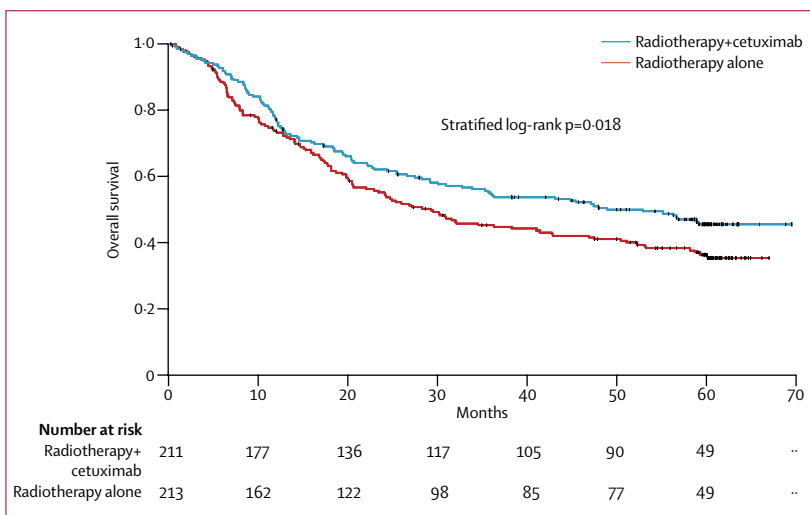


Figure 2: Overall survival by treatment: 5-year update (median follow-up 60 months)

confounding variables when assessing the relation between rash and survival.³⁵ The trial is registered at www.ClinicalTrials.gov, number NCT00004227.

Role of the funding source

Funding was provided for cetuximab treatments, data collection, statistical analysis, and the production of figures. The sponsors worked with the study chair (JAB) to develop the initial plan for randomisation. The plan was slightly modified to accommodate input from the initial meeting with potential investigators. The study chair (JAB) wrote the protocol. The sponsors contracted PharmaNet to provide clinical trial support involving stratification of patients and collection of data. The corresponding author had full access to all the data and final responsibility to submit the manuscript for publication.

Results

The trial recruited 424 patients between April, 1999, and

March, 2002, at 73 centres in the USA and 14 other countries in Europe, North America, Africa, and Oceania. 213 patients were randomly assigned to radiotherapy alone, and 211 were assigned to receive radiotherapy and cetuximab (figure 1). The treatment groups were well balanced with respect to stratification factors, other potential prognostic factors, and additional therapies such as elective neck dissections and other treatments (table 1). Although the median follow-up has been updated by less than 1 year since the last analysis, additional survival information has been obtained for 40% (76 patients) of the 188 patients who were alive at the time of the last analysis.²⁵

Median overall survival in the radiotherapy-alone group was 29.3 months (95% CI 20.6–41.4), compared with 49.0 months (32.8–69.5) in the cetuximab group. 5-year overall survival was 36.4% and 45.6%, respectively (hazard ratio [HR] 0.73, 95% CI 0.56–0.95; p=0.018; figure 2). In subgroup analyses, median overall survival values for patients who received cetuximab and radiotherapy versus radiotherapy alone were: American Joint Committee on Cancer (AJCC) T1–3 (69.5 vs 41.4 months, HR 0.66, 95% CI 0.48–0.92), AJCC N1–3 (53.0 vs 26.9 months, HR 0.71, 0.54–0.95), AJCC stage II–III (69.5 vs 46.9 months, HR 0.79, 0.47–1.35), and AJCC stage IV (43.2 vs 24.2 months, HR 0.76, 0.57–1.02).

We also assessed the potential associations of various patient and tumour factors with the effect of cetuximab on overall survival. A forest plot³³ was done to assess whether certain patient groups had an increased or decreased likelihood of improved survival with the addition of cetuximab to radiotherapy (figure 3). Patients with oropharyngeal tumours, early AJCC T stage (T1–3), treatment in the USA, concomitant boost, advanced AJCC N stage (N1–N3), high KPS (90–100), male sex, and age less than 65 years were factors associated with a potential increased benefit from cetuximab combined with radiotherapy versus radiotherapy alone. However, the trial was not powered for this subgroup analysis, and therefore these data should be interpreted with caution.

As expected, patients who received cetuximab had a greater number of grade 3 and 4 infusion reactions (3%) than did those who received radiotherapy alone, and more acneiform skin reactions (table 2). Information regarding late toxicity was not collected. Figure 4 shows the timing of the onset of the rash in the 174 patients from the cetuximab group who developed it. The cetuximab-induced rash began within 35 days of the initiation of treatment in 95% (167/174) of patients. Of the 208 patients who received cetuximab, 94% (195) received at least 7 doses, and 90% (187) received at least 1800 mg/m². There was no association between cumulative dose and rash (data not shown). Of the patients who received cetuximab, patients with a prominent rash had significantly longer overall survival compared with those with mild rash (68.8 months vs 25.6 months; HR 0.49, 0.34–0.72; p=0.002; figure 5).

This difference remained significant after stepwise Cox regression adjustments were made for KPS, age, and location of treatment.³⁵ The difference also remained significant after a sensitivity analysis excluding early deaths within 2 months of randomisation (data not shown). The small number of patients in the radiotherapy-alone group who developed acneiform rashes showed no survival difference compared with patients without rashes (data not shown). Since the cetuximab-induced rash showed a fairly consistent relation with survival across most subgroups, the rash was assessed in the group of patients with the worst prognosis: those with a KPS less than 90 (of the 61 patients who received cetuximab and had a KPS less than 90, 33 had mild rash and 28 had prominent rash). Even in this group, there was a suggestion (not significant) that the rash may be associated with longer survival (HR 0.67, 95% CI 0.38–1.17, $p=0.15$). Similar results were seen for patients aged >65 years (data not shown).

Discussion

Previously reported results from this trial showed better survival and locoregional disease control associated with cetuximab plus radiotherapy in patients with LASCCHN, relative to radiotherapy alone, and these differences were not associated with reduced quality of life or increased radiation-induced mucositis or dysphagia.^{25,34} This updated analysis was done to assess additional 5-year overall survival results. The long-term results corroborate the earlier findings that the addition of cetuximab to radiotherapy improved the survival of patients with LASCCHN. There was a difference of about 9% in absolute survival for the addition of cetuximab to radiotherapy compared with radiotherapy alone (36.4% vs 45.6%). Additionally, the subgroup analyses showed that patients given cetuximab who developed a prominent cetuximab-induced acneiform rash (grade 2–4) had better overall survival compared with patients given cetuximab who developed a mild or no rash (grade 0–1). The overall survival benefit associated with the addition of cetuximab to radiotherapy, relative to radiotherapy alone, is remarkably similar to that seen in the 3-year analysis (45% vs 55%),²⁵ which supports the validity of 3-year overall survival as a surrogate for long-term overall survival.

These updated survival results provide further support for considering the combination of cetuximab and radiotherapy as a standard option in the treatment of LASCCHN. Our previous report provided the impetus for the inclusion of cetuximab and radiotherapy as a treatment option for LASCCHN in the 2007 National Comprehensive Cancer Network (NCCN) guidelines.³⁶ Depending on the stage of disease, these guidelines include three treatment options that include radiotherapy as the cornerstone of treatment: radiotherapy alone, radiotherapy with concomitant systemic treatments such as cetuximab or cytotoxic chemotherapy, or

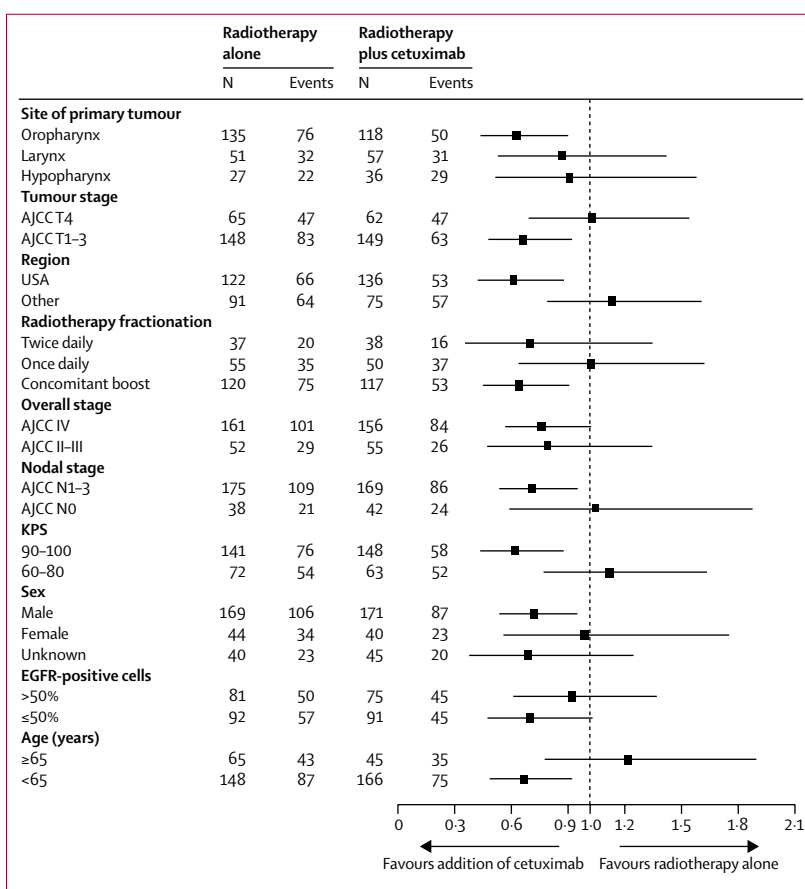


Figure 3: Overall survival by pre-treatment characteristics: 5-year update

AJCC=American Joint Committee on Cancer. KPS=Karnofsky performance score. EGFR=epidermal growth factor receptor.

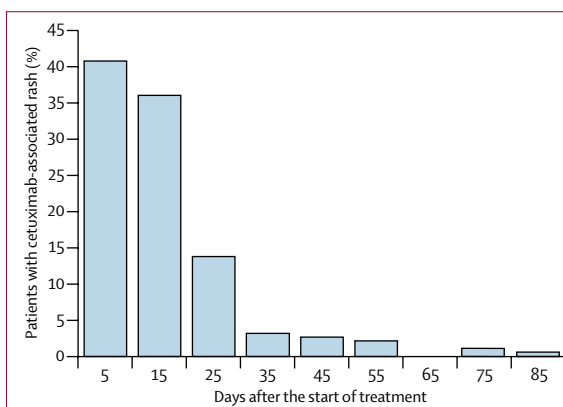


Figure 4: The onset of cetuximab-induced rash following the initiation of first treatment

sequential treatment of induction chemotherapy followed by concomitant chemoradiotherapy. The guidelines suggest that the intensity of treatment should be increased as the severity, or tumour burden, of LASCCHN increases. Further study is warranted to determine whether or not these severity-based

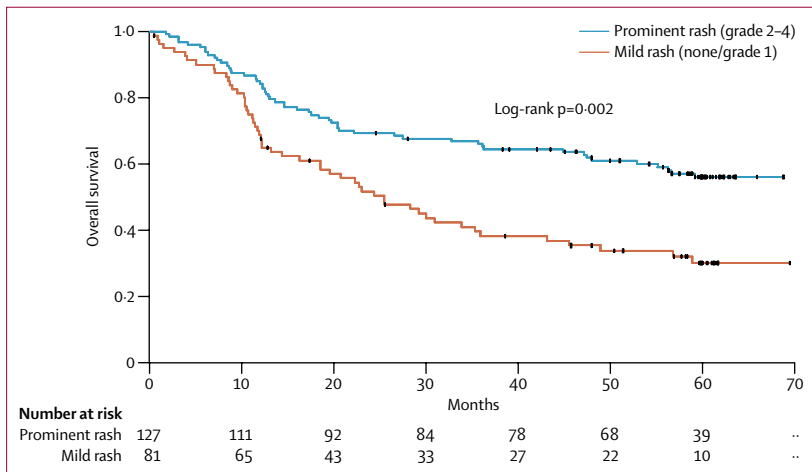


Figure 5: Overall survival by severity of rash in cetuximab-treated patients

recommendations are appropriate. To this end, a phase 3 RTOG 0522 trial assessing concurrent accelerated radiation and cisplatin versus concurrent accelerated radiation, cisplatin, and cetuximab for stage III and IV head and neck carcinomas recently closed to patient enrolment. Data from this trial will provide definitive information regarding cetuximab in combination with chemoradiation in the locally advanced disease setting, and provide the rationale for further exploration in earlier stages of disease.

The development of an acneiform rash is a toxicity that is frequently associated with cetuximab and not radiotherapy alone. Data from several studies across multiple cancers suggest a correlation between overall survival and the presence and/or intensity of cetuximab-induced acne-like rash.^{26–29} The present analysis examined the significance of acneiform rash in patients treated primarily with radiotherapy, since it has been associated with better survival in other treatment settings.²⁶ The characteristic cetuximab-induced acneiform rash arises during treatment and generally resolves completely in the first weeks following the cessation of therapy.³⁷ Of the 208 patients who received cetuximab and had information regarding skin toxicity, 174 (84%) patients had rash, and this incidence was similar to previous reports of cetuximab alone.³⁸ 127 patients had prominent rash, the remaining 81 patients had mild rash or none. Patients with prominent rash had more than 2.5 times longer overall survival than did patients with mild rash. It is possible that the acneiform rash is a biomarker of an immunological response that is conducive for optimal outcome. Further work will be necessary to determine the mechanistic significance of the acneiform rash. In the future, the presence or absence of a cetuximab-induced rash to identify patients who might benefit from more prolonged treatment with cetuximab or treatment with other agents. Preliminary investigations have assessed the use of maintenance cetuximab therapy.³⁹

The forest plot analysis (figure 3) of the effect of cetuximab in various subgroups showed some interesting associations that should be explored further in the future. Cetuximab seemed to provide the most benefit for patients with oropharyngeal tumours, T1–3 tumours, treatment in the USA, concomitant boost, advanced nodal stage, and high KPS. These subgroups represent small numbers of patients, and therefore the results might represent spurious findings. However, further work should be done to test the consistency of these results. Historically, patients with low KPS have done poorly with most treatments, and there was no suggestion that cetuximab benefited these patients. This finding has discouraged the use of cetuximab in these patients, as outlined by the National Institute for Health and Clinical Excellence in the UK.⁴⁰ However, even this most unfavourable population showed a suggestion that patients who achieved a prominent cetuximab rash did better than those who did not. Therefore, it might be possible to ascertain certain biological parameters of even the most unfavourable patient groups that could direct personalised treatment.

Since the publication of a meta-analysis⁴⁰ comparing chemoradiotherapy with radiotherapy alone, and other subsequent trials, the use of chemoradiotherapy has become a popular treatment option for patients with LASCCHN. However, the addition of cytotoxic chemotherapy to radiotherapy is not the ideal treatment for all patients. Patients must be able to tolerate the potential chemotherapy-induced side-effects and an exacerbation of radiation-induced mucositis and dysphagia. Cetuximab does not increase radiation-induced toxicities.^{39,41} A single institutional comparison of cetuximab and radiotherapy versus chemoradiotherapy in the treatment of patients with LASCCHN showed comparable survival results after correcting for potential confounding factors.⁴² These retrospective results confirm the need for a randomised trial comparing the efficacy and quality of life of the two treatments. Recently, preliminary results were presented from a randomised phase 2 trial that examined induction chemotherapy followed by radiotherapy with either concomitant chemotherapy (cisplatin) or concomitant cetuximab.⁴³ The preliminary results suggested no difference in local progression between the two therapeutic approaches, but cetuximab treatment was better tolerated than cisplatin. Future studies will be designed to help provide a pathway to individualised patient treatments. The analysis of molecular markers in the context of treatment outcomes will help refine our ability to select the patients who will benefit from the addition of various systemic treatments to radiotherapy.

In summary, these updated survival results show that cetuximab provides a long-term and clinically significant survival advantage (9% absolute survival advantage at 5 years) relative to radiotherapy alone for the

management of LASCCHN. These findings provide additional support for the recent inclusion of cetuximab in the NCCN Guidelines³⁶ as an accepted standard systemic therapy for patients with locoregionally advanced head and neck cancer.

Contributors

JAB, PMH, JG, RBC, CUJ, RKS, DR, JB, SAS, and KKA contributed to the recruitment and treatment of patients in the trial. JAB wrote the protocol. JAB, PMH, JG, RBC, DR, JB, SAS, JZ, HY, EKR, and KKA contributed to the design and analysis of the trial. All authors reviewed the manuscript before submission.

Conflicts of interest

JAB has been an occasional consultant, with honoraria for presentations, for Bristol-Myers Squibb, ImClone Systems, Merck KGaA, Oncolytics, and Sanofi-Aventis. PMH has laboratory research support from Amgen, Genentech, ImClone systems, and AstraZeneca. RBC has been a consultant for Bristol-Myers Squibb and ImClone Systems. CUJ has lectured for Bristol-Myers Squibb and ImClone Systems. DR has been an occasional consultant with AstraZeneca and Sanofi-Aventis. JAB, HY, and EKR are employed by ImClone Systems. All other authors declared no conflicts of interest.

Acknowledgments

This study was funded by ImClone Systems, Bristol-Myers Squibb, and Merck KGaA. The authors thank Gwen Sims for help with preparing the manuscript.

References

- Jesse RH. The evaluation of treatment of patients with extensive squamous cancer of the vocal cords. *Laryngoscope* 1975; **85**: 1424–29.
- Strong EW, Henschke UK, Nickson JJ, et al. Preoperative x-ray therapy as an adjunct to radical neck dissection. *Cancer* 1966; **19**: 1509–16.
- Peters LJ, Ang KK, Thames HD. Accelerated fractionation in the radiation treatment of head and neck cancer. *Acta Oncol* 1988; **27**: 185–94.
- Bryce DP, Rider WD. Pre-operative irradiation in the treatment of advanced laryngeal carcinoma. *Laryngoscope* 1971; **81**: 1481–90.
- The Department of Veterans Affairs Laryngeal Cancer Study Group. Induction chemotherapy plus radiation compared with surgery plus radiation in patients with advanced laryngeal cancer. *N Engl J Med* 1991; **324**: 1685–90.
- Bourhis J, Lapeyre M, Tortochaux J, et al. Phase III randomised trial of very accelerated radiation therapy compared with conventional radiation therapy in squamous cell head and neck cancer: a GORTEC Trial. *J Clin Oncol* 2006; **24**: 2873–78.
- Fu KK, Pajak TF, Trotti A, et al. A Radiation Therapy Oncology Group (RTOG) phase III randomised study to compare hyperfractionation and two variants of accelerated fractionation to standard fractionation radiotherapy for head and neck squamous cell carcinomas: first report of RTOG 9003. *Int J Radiat Oncol Biol Phys* 2000; **48**: 7–16.
- Adelstein DJ, Li Y, Adams GL, et al. An intergroup phase III comparison of standard radiation therapy and two schedules of concurrent chemoradiotherapy in patients with unresectable squamous cell head and neck cancer. *J Clin Oncol* 2003; **21**: 92–98.
- Calais G, Alfonsi M, Bardet E, et al. Randomised trial of radiation therapy versus concomitant chemotherapy and radiation therapy for advanced-stage oropharynx carcinoma. *J Natl Cancer Inst* 1999; **91**: 2081–86.
- Pignon JP, le Maitre A, Maillard E, et al. Meta-analysis of chemotherapy in head and neck cancer (MACH-NC): an update on 93 randomised trials and 17,346 patients. *Radiation Oncol* 2009; **92**: 4–14.
- Bourhis J, Overgaard J, Audry H, et al. Hyperfractionated or accelerated radiotherapy in head and neck cancer: a meta-analysis. *Lancet* 2006; **368**: 843–54.
- Staar S, Rudat V, Stuetzer H, et al. Intensified hyperfractionated accelerated radiotherapy limits the additional benefit of simultaneous chemotherapy—results of a multicentric randomised German trial in advanced head-and-neck cancer. *Int J Radiat Oncol Biol Phys* 2001; **50**: 1161–71.
- Bonner JA, Raisch KP, Trummell HQ, et al. Enhanced apoptosis with combination C225/radiation treatment serves as the impetus for clinical investigation in head and neck cancers. *J Clin Oncol* 2000; **18** (suppl): 47S–53S.
- Grandis JR, Melhem MF, Gooding WE, et al. Levels of TGF- α and EGFR protein in head and neck squamous cell carcinoma and patient survival. *J Natl Cancer Inst* 1998; **90**: 824–32.
- Ang KK, Berkey BA, Tu V, et al. Impact of epidermal growth factor receptor expression on survival and pattern of relapse in patients with advanced head and neck carcinoma. *Cancer Res* 2002; **62**: 7350–56.
- Bonner JA, Maihle NJ, Folven BR, Christianson TJH, Spain K. The interaction of epidermal growth factor and radiation in human head and neck squamous cell carcinoma cell lines with vastly different radiosensitivities. *Int J Radiat Oncol Biol Phys* 1994; **29**: 243–47.
- Huang SM, Bock JM, Harari PM. Epidermal growth factor receptor blockade with C225 modulates proliferation, apoptosis, and radiosensitivity in squamous cell carcinomas of the head and neck. *Cancer Res* 1999; **59**: 1935–40.
- Saleh MN, Raisch KP, Stackhouse MA, et al. Combined modality therapy of A431 human epidermoid cancer using anti-EGFr antibody C225 and radiation. *Cancer Biother Radiopharm* 1999; **14**: 451–63.
- Goldstein N, Prewett M, Zuklys K, et al. Biological efficacy of a chimeric antibody to the epidermal growth factor receptor in a human tumor xenograft model. *Clin Cancer Res* 1995; **1**: 1311–18.
- Mendelsohn J. Epidermal growth factor receptor inhibition by a monoclonal antibody as anticancer therapy. *Clin Cancer Res* 1997; **3**: 2703–07.
- Fan Z, Masui H, Altas I, et al. Blockade of epidermal growth factor receptor function by bivalent and monovalent fragments of 225 anti-epidermal growth factor receptor monoclonal antibodies. *Cancer Res* 1993; **53**: 4322–28.
- Li S, Schmitz KR, Jeffrey PD, et al. Structural basis for inhibition of the epidermal growth factor receptor by cetuximab. *Cancer Cell* 2005; **7**: 301–11.
- Fan Z, Lu Y, Wu X, et al. Antibody-induced epidermal growth factor receptor dimerization mediates inhibition of autocrine proliferation of A431 squamous carcinoma cells. *J Biol Chem* 1994; **269**: 27595–602.
- Robert F, Ezekiel MP, Spencer SA, et al. Phase I study of anti-epidermal growth factor receptor antibody cetuximab in combination with radiation therapy in patients with advanced head and neck cancer. *J Clin Oncol* 2001; **19**: 3234–43.
- Bonner JA, Harari PM, Giralt J, et al. Radiotherapy plus cetuximab for squamous-cell carcinoma of the head and neck. *N Engl J Med* 2006; **354**: 567–78.
- Jonker DJ, O'Callaghan CJ, Karapetis CS, et al. Cetuximab for the treatment of colorectal cancer. *N Engl J Med* 2007; **357**: 2040–48.
- Saltz LB, Kies MS, Abbruzzese JL, et al. The presence and intensity of the cetuximab-induced acne-like rash predicts increased survival in studies across multiple malignancies. *Proc Am Soc Clin Oncol* 2003; **21** (suppl): abstr 817.
- Rougier P, Stroiakovski D, Köhne C, et al. Addition of cetuximab to FOLFIRI in first-line metastatic colorectal cancer (mCRC): updated survival data and influence of KRAS status on outcome in the CRYSTAL study. American Society of Clinical Oncology (ASCO) Gastrointestinal Cancers Symposium. San Francisco, CA, USA; Jan 15–17, 2009. abstr 443.
- Gatzemeier U, von Pawel J, Vynnychenko I, et al. FLEX: cetuximab in combination with platinum-based chemotherapy (CT) improves survival versus CT alone in the 1st-line treatment of patients (pts) with advanced non-small cell lung cancer (NSCLC). Chicago Multidisciplinary Symposium in Thoracic Oncology. Chicago, IL, USA; Nov 13–15, 2008. abstr 8.
- Cox JD, Stetz J, Pajak TF. Toxicity criteria of the Radiation Therapy Oncology Group (RTOG) and the European Organization for Research and Treatment of Cancer (EORTC). *Int J Radiat Oncol Biol Phys* 1995; **31**: 1341–46.
- Pocock SJ, Simon R. Sequential treatment assignment with balancing for prognostic factors in the controlled clinical trial. *Biometrics* 1975; **31**: 103–15.
- Mantel N. Evaluation of survival data and two new rank order statistics arising in its consideration. *Cancer Chemother Rep* 1966; **50**: 163–170.

- 33 Lewis S, Clarke M. Forest plots: trying to see the wood and the trees. *BMJ* 2001; **322**: 1479–80.
- 34 Curran D, Giralt J, Harari PM, et al. Quality of life in head and neck cancer patients after treatment with high-dose radiotherapy alone or in combination with cetuximab. *J Clin Oncol* 2007; **25**: 2191–97.
- 35 Cox DR. Regression models and life tables. *J R Stat Soc B* 1972; **34**: 187–220.
- 36 National Comprehensive Cancer Network. The NCCN Clinical Practice Guidelines in Oncology Head and Neck Cancers (Version 1, 2007). http://www.nccn.org/professionals/physician_gls/f_guidelines.asp (accessed April 1, 2009).
- 37 Bonner J, Harari PM, Giralt J, et al. The relationship of cetuximab-induced rash and survival in patients with head and neck cancer treated with radiotherapy and cetuximab. *Int J Radiat Oncol Biol Phys* 2005; **63** (suppl 1): S73.
- 38 Lenz JH, Cutsem EV, Khambata-Ford S, et al. Multicenter phase II and translational study of cetuximab in metastatic colorectal carcinoma refractory to irinotecan, oxaliplatin, and fluoropyrimidines. *J Clin Oncol* 2006; **24**: 4914–21.
- 39 Langer CJ, Lee JW, Patel UA, et al. Preliminary analysis of ECOG 3303: Concurrent radiation (RT), cisplatin (DDP) and cetuximab (C) in unresectable, locally advanced (LA) squamous cell carcinoma of the head and neck (SCCHN). *Proc Am Soc Clin Oncol* 2008; **26** (suppl): abstr 6006.
- 40 National Institute for Health and Clinical Excellence. Technology appraisal guidance 145, Cetuximab for the treatment of locally advanced squamous cell cancer of the head and neck. <http://guidance.nice.org.uk/TA145> (accessed Sept 10, 2009).
- 41 Caudell JJ, Schaner PE, Meredith RF, et al. Factors associated with long-term dysphagia after definitive radiotherapy for locally advanced head-and-neck cancer. *Int J Radiat Oncol Biol Phys* 2009; **73**: 410–15.
- 42 Caudell JJ, Sawrie SM, Spencer SA, et al. Locoregionally advanced head and neck cancer treated with primary radiotherapy: a comparison of the addition of cetuximab or chemotherapy and the impact of protocol treatment. *Int J Radiat Oncol Biol Phys* 2008; **71**: 676–81.
- 43 Lefebvre J, Pointreau Y, Rolland F, et al. Sequential chemoradiotherapy (SCRT) for larynx preservation (LP): Preliminary results of the randomised phase II TREMPILIN study. *Proc Am Soc Clin Oncol* 2009; **27** (suppl): 303s.